



PATIENT

Bear O'Brien

PRESENTING CLINICAL SIGNS

History: Admitted for trouble breathing this past weekend - started on furosemide.

SPECIES

Feline

ECHOCARDIOGRAM FINDINGS

2D, m-mode, color flow and doppler imaging is available. The left ventricular wall is normal with regions of remodeling and irregularity. There is a diffusely hyperechoic endocardium consistent with fibrosis. Moderator bands. Mild LV dilation. The systolic function is decreased with evidence of diastolic dysfunction as well. The papillary muscles are mildly remodeled. The left atrium is severely dilated. No obvious spontaneous contrast; no obvious thrombus. Mild central MR due to annular stretch. The right ventricle is also affected, with diffuse fibrosis and remodeling. Mild RA dilation. Mild central TR. Blood flow through the RVOT and LVOT is low normal velocity. No pericardial or pleural effusion. No obvious cardiac tumors.

BREED

DMH

SEX

Male Neutered

CARDIAC CHART

AGE

13 years

WEIGHT

14.9lbs

INTERPRETED BY

Maggie Machen Lamy,
DVM, DACVIM
(Cardiology)

FELINE CARDIAC PARAMETERS	BODY WEIGHT (kg)	HR (BPM)	IVSd (cm) (Moise, Pipers)	LVIDd (cm) (Moise, Pipers)	LWVd (cm) (Moise, Pipers)	FS (%)	EF (%)
NORMAL PARAMETER	-----	150-240	0.35-0.55	<2 (mean 1.5)	3.5-0.55	35-67	80-100
PATIENT	6.8	230	0.36	2.2	0.39	32	60
FELINE CARDIAC PARAMETERS	LA/AO (Boon)	LA/AO HEART BASE (Swe) (Abbott)	LA 2D short axis Base view (cm) (Abbott)		LVOT VEL (m/s)	RVOT VEL (m/s)	E max (m/s)
NORMAL	<1.5	<1.3	<1.2		<1.6	<1.3	<0.9
PATIENT	2.0	2.1	1.7		0.7	0.6	NM

**Note: All measurements based upon multi-modal images and methods. An average value is reported.
Adapted from June Boon, Veterinary Echocardiography, 1998
Abbott J & MacLean H JVIM 2006;20: 111-119, Moise et al. Am J Vet Res 47:1476, 1986. Pipers et al. Am J Vet Res 40:882, 1979.*

IMAGING PERFORMED BY

Diane McFadden

HOSPITAL NAME

Newton Veterinary Hospital

REFERRING VET

Dr. Wyman Greenwald

INVOICE

26266

DATE

9/8/22

INTERPRETATION OF THE FINDINGS & FURTHER RECOMMENDATIONS

The finding of severe biatrial enlargement in the face of normal/decreased LV wall thickness and systolic dysfunction is most consistent with Restrictive Cardiomyopathy (RCM), however some historical infectious or inflammatory insult to the myocardium cannot be definitively ruled out. The biatrial dilation is causing insufficiency of both AV valves, and systolic dysfunction has developed.

The finding of this degree of biatrial dilation confirms the origin of recent tachypnea is spontaneous congestive heart failure, and continued lifelong medications are warranted as below. This patient is at high risk for thromboembolic events regardless of medications and this should be expressed to the owner (monitor for neurologic change, acute paralysis/lameness, etc.). The prognosis is poor to grave, with a mean survival time for cats with CHF <8-12 months, however most are able to maintain a good quality of life on medications if able to be stabilized. There will always remain risk for recurrent episodes of CHF, development of blood clots, arrhythmias, and/or sudden death in the future. Monitoring of sleeping breathing rates at home is recommended as the best way to screen for recurrent CHF at home.



PATIENT

Bear O'Brien

SPECIES

Feline

BREED

DMH

SEX

Male Neutered

AGE

13 years

WEIGHT

14.9lbs

INTERPRETED BY

Maggie Machen Lamy,
DVM, DACVIM
(Cardiology)

IMAGING PERFORMED BY

Diane McFadden

HOSPITAL NAME

Newton Veterinary
Hospital

REFERRING VET

Dr. Wyman
Greenwald

INVOICE

26266

DATE

9/8/22

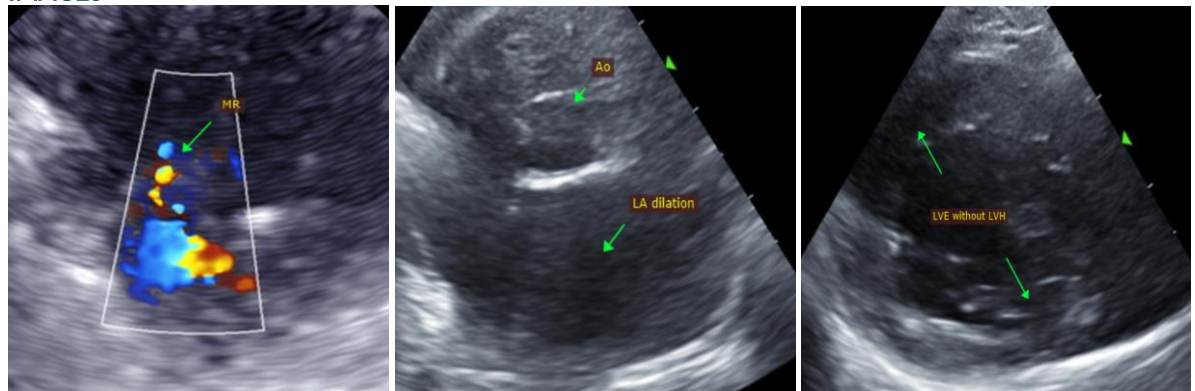
PLAN

Oral medications: furosemide 1-2mg/kg PO q12h. Institute blood thinner Clopidogrel (Plavix) 75mg tablets; give ¼ tab orally once daily (NOTE: this medication is very bitter on the cut edges). Institute Pimobendan (off label use) 0.625mg PO q12h.

Once stabilized, eating well at home and BP >130mmHg, consider addition of vasodilator ACE-I (benazepril or enalapril) 0.5mg/kg PO q12h.

Recheck renal values in 10-14 days to ensure tolerance of medications, then every 3-4 months lifelong. A recheck echocardiogram is recommended in 4-6 months to assess for progression.

IMAGES



The information and recommendations provided are based on the images presented by the referring veterinarian. No evaluation can be communicated regarding pathology that was not visible in the image/video clips provided.

Thank you for this referral. This report was generated using transcription software, and minor dictation errors may be present. If the clinical or image interpretation does not parallel your findings or if I can be of any further assistance, please contact me.

Maggie Machen Lamy, DVM
Diplomate of the American College of Veterinary Internal Medicine (Cardiology)
info@sonopath.com